ADVANCED
VETERINARY MEDICAL IMAGING

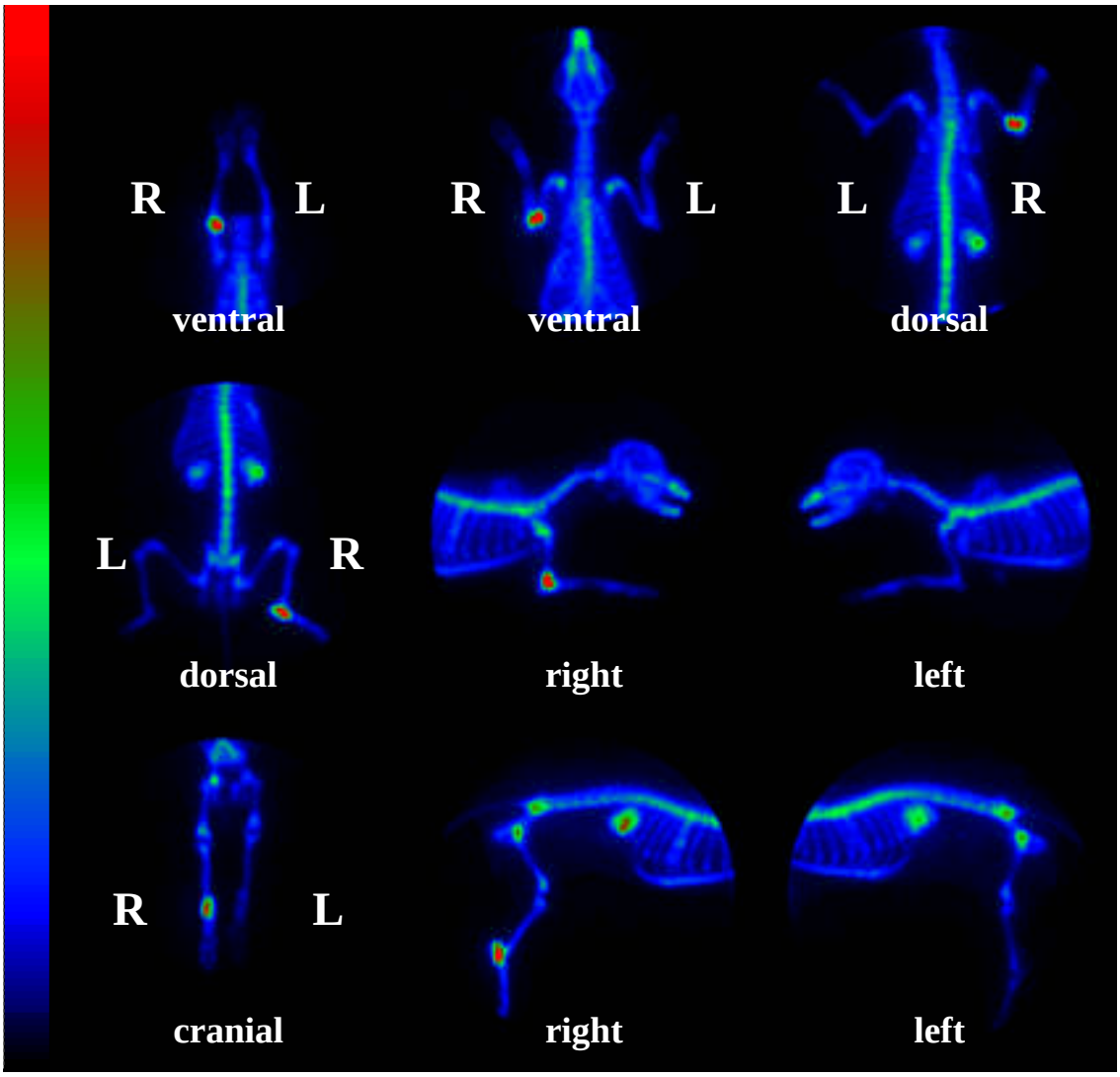

Planar Bone Scintigraphy

Species: Canine Breed: Chihuahua

Age: 14 years Sex: female

Isotope: ^{99m}Tc Chemical Form: MDP

History: Previous history of pulmonary carcinoma treated with lobectomy. Recent onset of pain and swelling of the right tarsal region.

Interpretation: This pattern is most consistent with metastatic disease involving the right tarsus and distal humerus. The diffusely increased radionuclide uptake noted in the 6th and 7th ribs on the right is typical for a post-thoracotomy change.

3047 Edinger Ave • Tustin • CA • 92780 • Tel: 949-559-7289 • Fax: 949-559-6727
2340 Sepulveda Blvd. • Los Angeles • CA • 90064 • Tel: 310-477-4453 • Fax: 949-559-6727