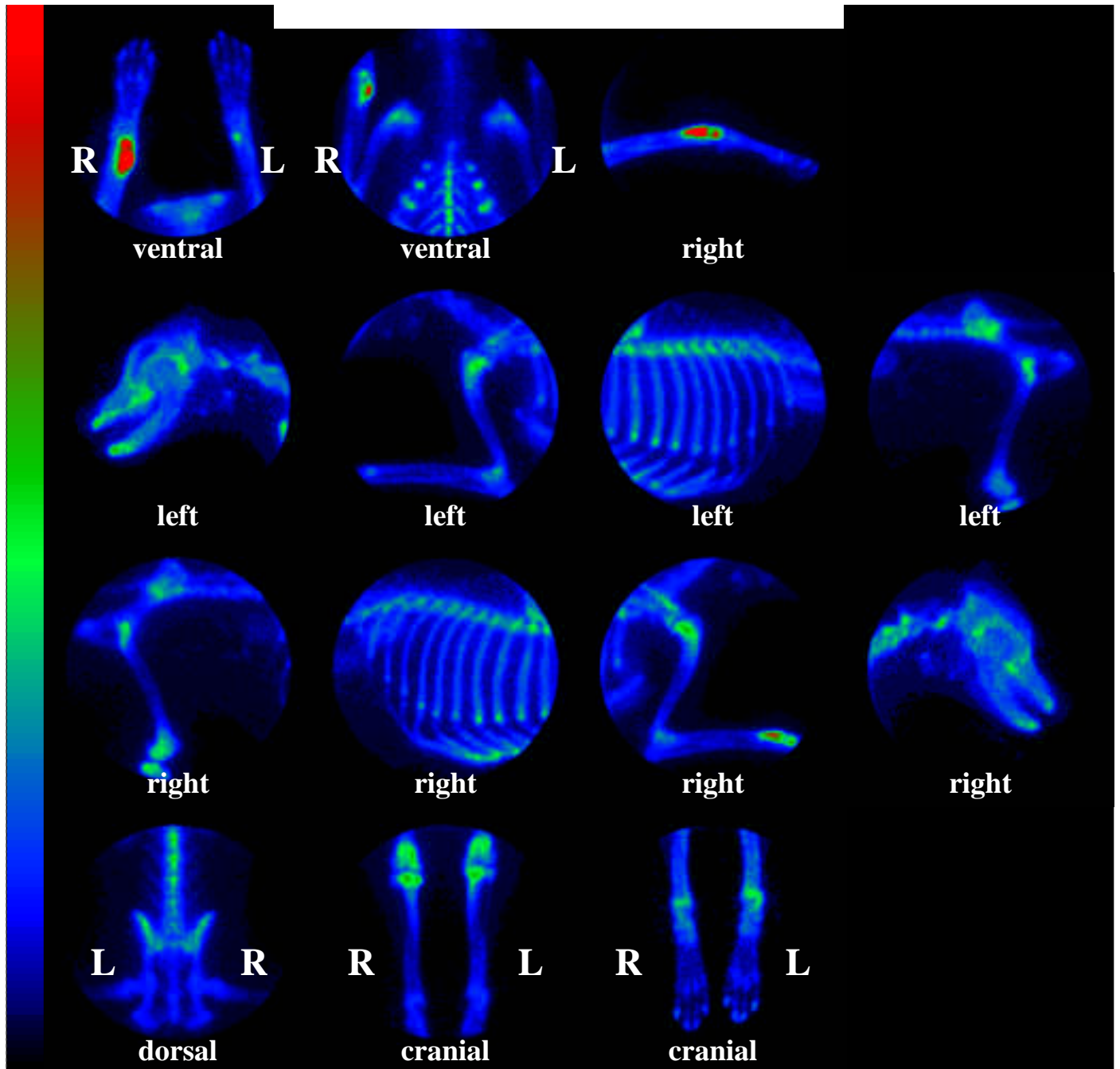




ADVANCED

VETERINARY MEDICAL IMAGING



Planar Bone Scintigraphy

Species: Canine
Age: 7 years
Isotope: ^{99m}Tc

Breed: Rottweiler
Sex: male
Chemical Form: MDP

Interpretation: This pattern is most consistent with a primary bone neoplasia of the distal right radius. The bilaterally increased radionuclide uptake noted in both stifle joints is typical for chronic DJD.